

Geographic Atrophy (GA): Quick Reference Guide

Optometrists play a key role in diagnosing and referring GA¹

GA is an advanced form of age-related macular degeneration (AMD).^{2,3} It affects ~1 million people in the US.⁴

GA prevalence **increases with age**, rising from 0.16% at age 60 to 2.91% at age 80.⁵

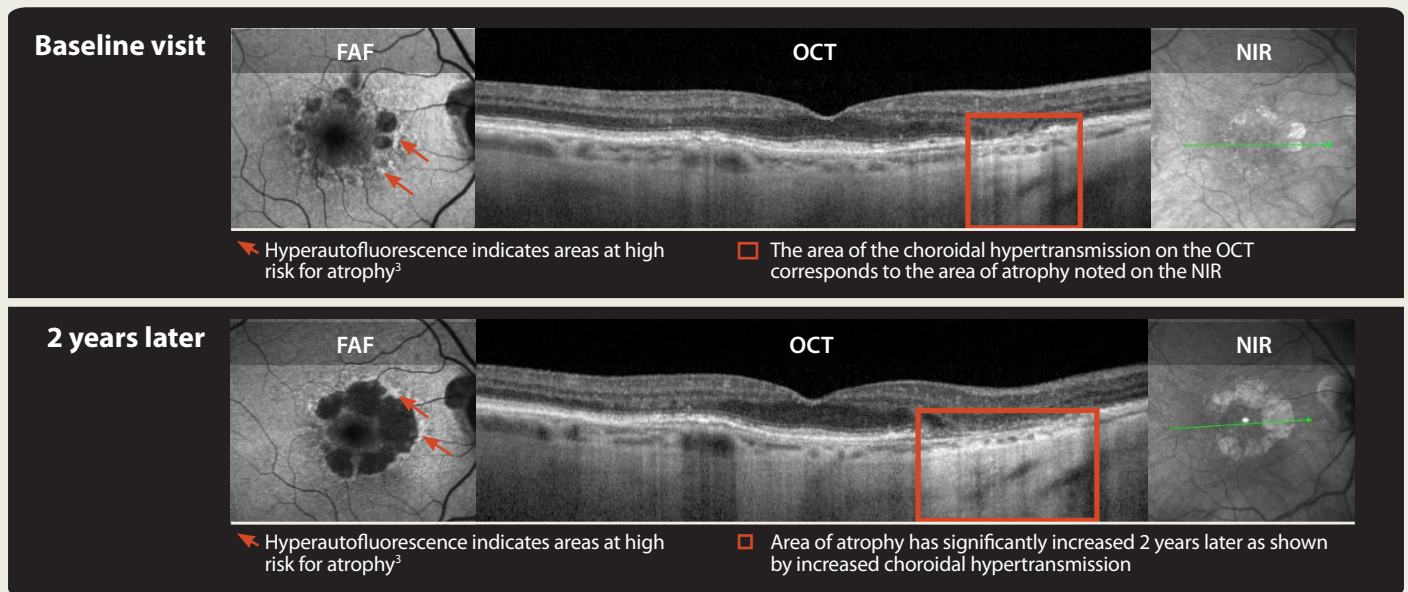
GA and wet AMD are **different manifestations** of advanced AMD.^{2,3}

The overall prevalences of GA and wet AMD are **similar**.^{4,6*}

While GA progression can appear to move slowly, it can affect your patients faster than you think.⁷⁻¹⁰

Of the 397 patients who developed central GA, the **median time to foveal encroachment** was only 2.5 years from diagnosis according to a prospective AREDS study (N=3640).^{11†}

GA can be diagnosed and monitored through multimodal imaging



Images courtesy of Mohammad Rafieetay, OD, Charles Retina Institute.
FAF=fundus autofluorescence; NIR=near infrared; OCT=optical coherence tomography.

It is critical to diagnose and refer patients with GA as early as possible because the damage is progressive and associated with irreversible vision loss.^{3,7}

Visual acuity (VA) is poorly correlated with GA lesion size, and change in VA may not fully capture disease progression.^{7,12} Functional vision continues to decline as lesions grow.^{7,9,10}



In a retrospective study (n=523), **2 OUT OF 3 PATIENTS** with bilateral GA lost the ability to drive in a median time of <2 years from the earliest record indicating diagnosis of GA.^{13‡}



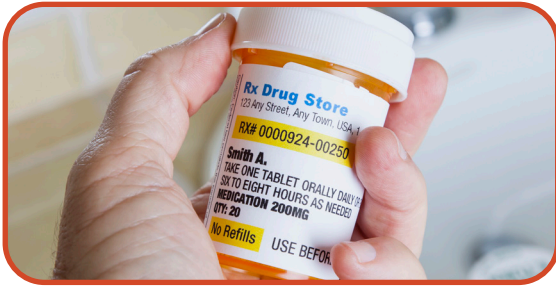
According to a survey conducted by The Harris Poll and sponsored by Apellis Pharmaceuticals (N=203), **68% OF PATIENTS** living with GA reported a major/ moderate negative impact on their ability to read.¹⁴

*Prevalences of GA and Wet AMD in the US are ~973,000 and ~1.2M respectively.⁴

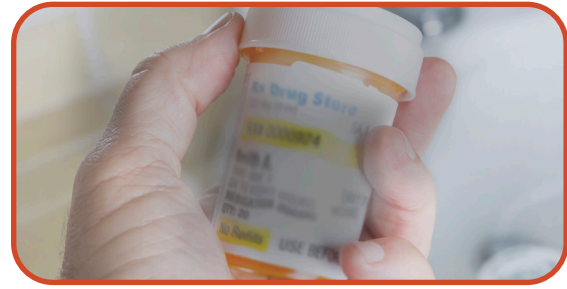
†Lesions encroached on the fovea in a median of just 2.5 years in AREDS #26, a long-term, multicenter, prospective study examining progression of GA area in a cohort of 3640 patients with signs of early and more advanced forms of AMD.¹¹

‡A retrospective cohort study (N=1901) of a multicenter electronic medical record database examining disease burden and progression in patients in the United Kingdom with bilateral GA secondary to AMD.¹³

Normal vision



See through the eyes of a patient living with GA*



Some patients living with GA describe their visual impairment as blurriness, waviness, or areas that are missing. This may lead to difficulty reading or seeing faces.^{15,16}

*Representation of vision loss for illustrative purposes only.

Learn more about GA at RecognizeAndReferGA.com

References: 1. American Optometric Association. AOA Comprehensive adult eye and vision examination. Quick Reference Guide: Evidence-Based Clinical Practice Guideline. 1st ed. American Optometric Association 2015. Accessed June 29, 2022. https://www.aoa.org/documents/EBO/Comprehensive_Adult_Eye_and_Vision%20QRG.pdf. 2. Kaszubski P, Ben Ami T, Saade C, Smith RT. Geographic atrophy and choroidal neovascularization in the same eye: A Review. *Ophthalmic Res.* 2016;55(4):185-193. doi:10.1159/000443209. 3. Fleckenstein M, Mitchell P, Freund KB, et al. The progression of geographic atrophy secondary to age-related macular degeneration. *Ophthalmology.* 2018;125(3):369-390. doi:10.1016/j.ophtha.2017.08.038. 4. Friedman DS, O'Colmain BJ, Muñoz B, et al. Prevalence of age-related macular degeneration in the United States. *Arch Ophthalmol.* 2004;122(4):564-572. doi:10.1001/archophth.122.4.564. 5. Rudnicka AR, Jarrar Z, Wormald R, Cook DG, Fletcher A, Owen CG. Age and gender variations in age-related macular degeneration prevalence in populations of European ancestry: a meta-analysis. *Ophthalmology.* 2012;119(3):571-580. doi:10.1016/j.ophtha.2011.09.027. 6. Wong WL, Su X, Li X, et al. Global prevalence of age-related macular degeneration and disease burden projection for 2020 and 2040: a systematic review and meta-analysis. *Lancet Glob Health.* 2014;2(2):e106-116. doi:10.1016/S2214-109X(13)70145-1. 7. Boyer DS, Schmidt-Erfurth U, van Lookeren Campagne M, Henry EC, Brittain C. The pathophysiology of geographic atrophy secondary to age-related macular degeneration and the complement pathway as a therapeutic target. *Retina.* 2017;37(5):819-835. doi:10.1097/iae.0000000000001392. 8. Sunness JS, Margalit E, Srikumaran D, et al. The long-term natural history of geographic atrophy from age-related macular degeneration: enlargement of atrophy and implications for interventional clinical trials. *Ophthalmology.* 2007;114(2):271-277. doi:10.1016/j.ophtha.2006.09.016. 9. Kimel M, Leidy NK, Tschosik E, et al. Functional reading independence (FRI) index: A new patient-reported outcome measure for patients with geographic atrophy. *Invest Ophthalmol Vis Sci.* 2016;57(14):6298-6304. doi:10.1167/iovs.16-20361. 10. Sadda SR, Chakravarthy U, Birch DG, Staurenghi G, Henry EC, Brittain C. Clinical endpoints for the study of geographic atrophy secondary to age-related macular degeneration. *Retina.* 2016;36(10):1806-1822. doi:10.1097/IAE.0000000000001283. 11. Lindblad AS, Lloyd PC, Clemons TE, et al; Age-Related Eye Disease Study Research Group. Change in area of geographic atrophy in the age-related eye disease study: AREDS report number 26. *Arch Ophthalmol.* 2009;127(9):1168-1174. doi:10.1001/archophthol.2009.198. 12. Heier JS, Pieramici D, Chakravarthy U, et al. Visual function decline resulting from geographic atrophy: results from the chroma and spectri phase 3 trials. *Ophthalmol Retina.* 2020;4(7):673-688. doi:10.1016/j.oret.2020.01.019. 13. Chakravarthy U, Bailey CC, Johnston RL, et al. Characterizing disease burden and progression of geographic atrophy secondary to age-related macular degeneration. *Ophthalmology.* 2018;125(6):842-849. doi:10.1016/j.ophtha.2017.11.036. 14. Data on File, Apellis Pharmaceuticals, Inc. Apellis GA Survey Final Report. 15. Sacconi R, Corbelli E, Querques L, Bandello F, Querques G. A review of current and future management of geographic atrophy. *Ophthalmol Ther.* 2017;6(1):69-77. doi:10.1007/s40123-017-0086-6. 16. Taylor DJ, Edwards LA, Binns AM, Crabb DP. Seeing it differently: self-reported description of vision loss in dry age-related macular degeneration. *Ophthalmic Physiol Opt.* 2018;38:98-105.